

# BENEFITS OF ROUTINE NIPPLE MARKING IN MAMMOGRAPHY

By Deborah A. Berger, M.D. • Radiologist, Physician Consultant

Routine identification of the nipple with a skin marker in both screen-film and digital mammography on all patients eliminates uncertainty and the necessity for any repeat examinations. Many mammography facilities use a small self-adhesive skin marker to readily identify the nipple. A nipple marker is placed on the patient before her mammogram and subsequently serves as a reliable and stable landmark on mammograms for the registration of multiple images.

Placement of nipple markers not only provides a high quality examination for the patient, they also aid the radiologist in reading the mammogram by eliminating confusion and saving time.

Accurate identification of nipple location on mammograms can be challenging because of variations in image quality and in the nipple projections.

This can result in some nipples being nearly invisible on the image. The small radiopaque marker placed on each nipple allows the nipple to be viewed as a reference point on the film for concise nipple-to-lesion distance, helpful in cases with subareolar masses, and in the post-surgical breast with architectural distortion.

Disposable nipple markers make routine nipple marking in mammography possible because they are readily accepted by the patient, easy to use, and cause no significant patient delay. Using nipple markers helps to eliminate the cost of repeat examinations. In addition to the actual cost for the repeat examination there is the hidden cost of time lost at work for those outpatients who had to return for additional radiographs. Of even greater importance to the patient is the anxiety generated by the report needed for additional imaging which can be eliminated with routine nipple marking.

## SUBAREOLAR MASSES

Nipple markers are particularly helpful in cases with subareolar masses. Depth divides the breast arbitrarily into anterior, middle and posterior thirds, and immediately behind the nipple is the subareolar region.

When a nipple marker is not used it can be difficult to distinguish the nipple from a well-circumscribed mass in the subareolar region. Additional imaging would be required which may invoke unnecessary anxiety for the patient.

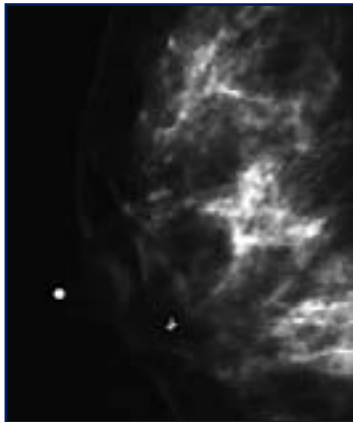


Figure 1: R-MLO

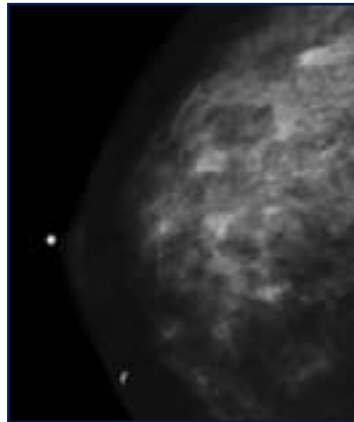


Figure 2: R-CC

### Case 1

A 39 year-old female with a history of a tender palpable right breast mass which underwent ultrasound guided core needle biopsy with results compatible with a fibroadenoma. Previously behind the right nipple is one bilobed mass versus two separate nodules. (A biopsy clip is noted to be positioned 1.5cm medial to the most medial portion of the lesion.) The fibroadenoma in this case is just beneath the skin surface. The nipple marker is extremely useful to eliminate any uncertainty in identifying the mass from the nipple.

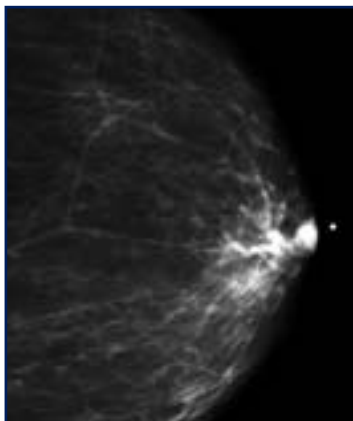


Figure 1: L-CC

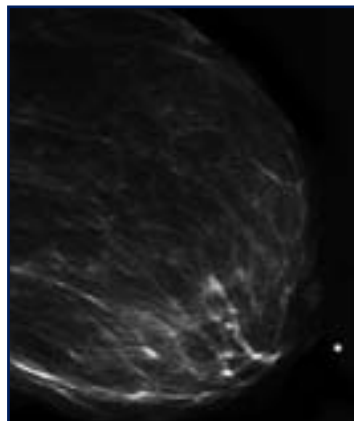


Figure 2: L-MLO

### Case 2

An asymptomatic 72 year-old female with a stable 1cm well-circumscribed mass directly behind the left nipple since 2002. The mass is slightly superior on the MLO view. The nipple marker is extremely useful to quickly identify the mass from the nipple.

## NIPPLE-TO-LESION DISTANCE

Placement of nipple markers allows accurate measurement of lesions and their distance from the nipple. Findings on mammographic images are generally reported with the o'clock position and distance from the nipple. If a potential lesion can only be identified in one view additional workup is required and every effort needs to be made to determine its location in another projection.

Using the nipple-to-lesion distance can aid in lesion identification. By determining how far back from the nipple the lesion is on one view the approximate location of the lesion can then be ascertained on the other projection. If two views are not sufficient for lesion identification, triangulation of the lesion with additional imaging is then warranted.

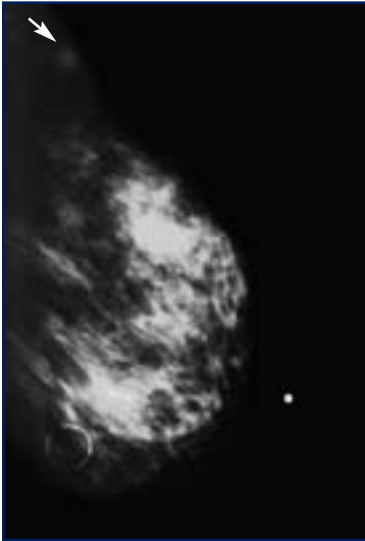


Figure 1: L-MLO

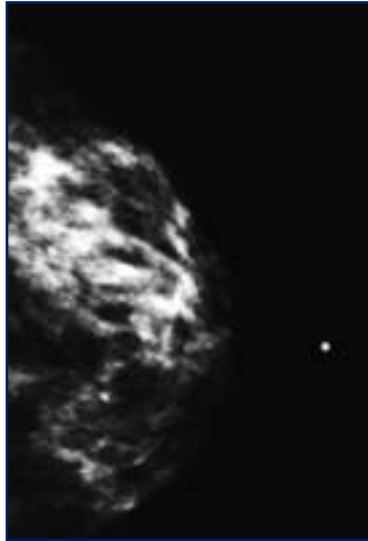


Figure 2: L-CC

### Case 3

A 72 year-old female presented for a screening mammogram. Within the superior aspect of the left breast 15cm posterior to the nipple on the MLO view is a 5mm ill-defined mass. To determine a more precise location for the mass the craniocaudal (CC) view is reviewed. In this example the medial aspect of the breast 15cm posterior to the nipple is clean with no masses. Therefore, based on location and its distance from the nipple using the MLO view this lesion is likely in the far posterior and lateral aspect of the breast on the CC view at approximately one to two o'clock where there is the suggestion of a mass. Additional imaging including a standard 90 degree lateral view and spot compression views were performed along with an ultrasound and ultrasound guided biopsy (not shown). The biopsy findings were compatible with infiltrating lobular carcinoma.

## SUBOPTIMAL EXPOSURE

Variations in image quality can make accurate identification of the skin line and of the nipple difficult. The absence of the nipple as a stable landmark in these circumstances generates additional read time for the radiologist. The generally simple registration of medial from lateral on the CC view and superior from inferior

on the MLO view is challenged when the nipple and skin line are not visualized. Even with the advent of digital mammography nipple markers continue to be beneficial. The markers allow immediate identification of the nipple without adjusting the window and level settings.

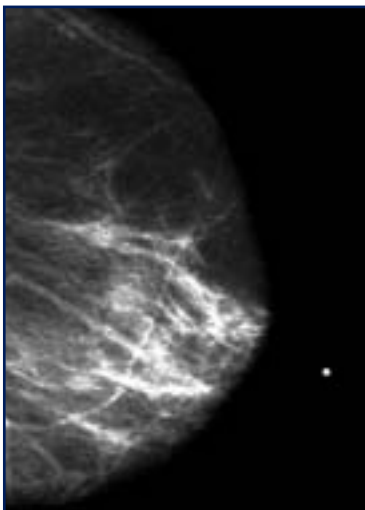


Figure 1: L-MLO

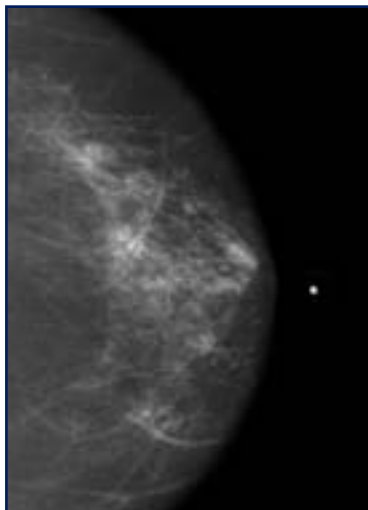


Figure 2: L-CC

### Case 4

A 74 year-old female presented for a screening mammogram. The skin surface cannot be seen and the use of a nipple marker allows the nipple to be identified.

## POST-SURGICAL ARCHITECTURAL DISTORTION

In patients with a history of lumpectomy or reconstructive breast surgery there can be significant post-surgical architectural distortion which not only affects the appearance of the breast parenchyma but can also alter the position of the nipple.

Without placement of nipple markers during initial and subsequent post-surgical imaging, the nipple may be mistaken for a mass requiring additional imaging.

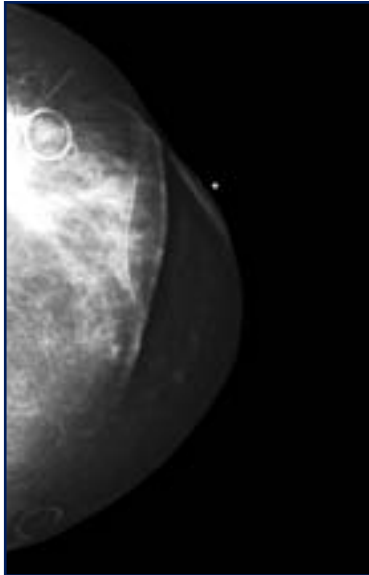


Figure 1: L-CC

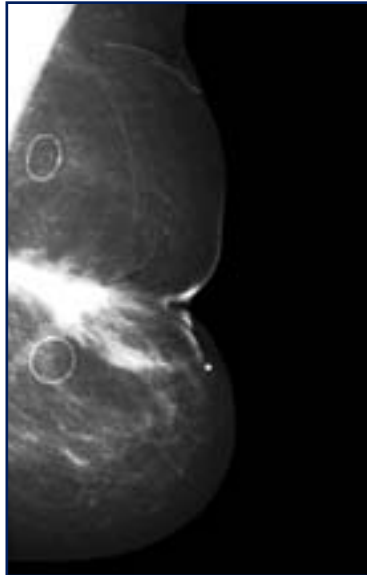


Figure 2: L-MLO

### Case 5

A 42 year-old female with a history of left lumpectomy for malignancy. She has additional history of reduction surgery performed many years prior to lumpectomy surgery. The nipple in these images is markedly displaced by post-surgical changes identified with a nipple marker.

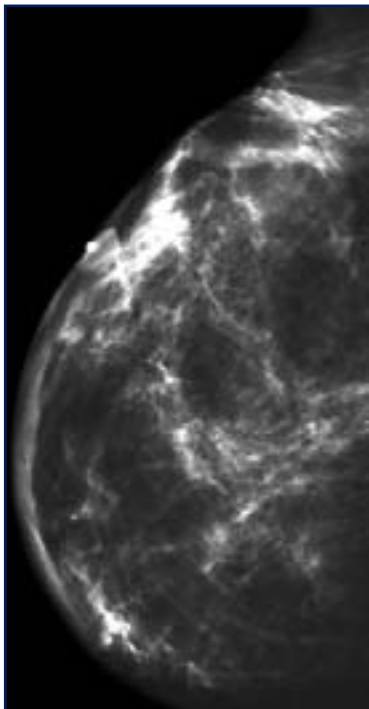


Figure 1: R-MLO

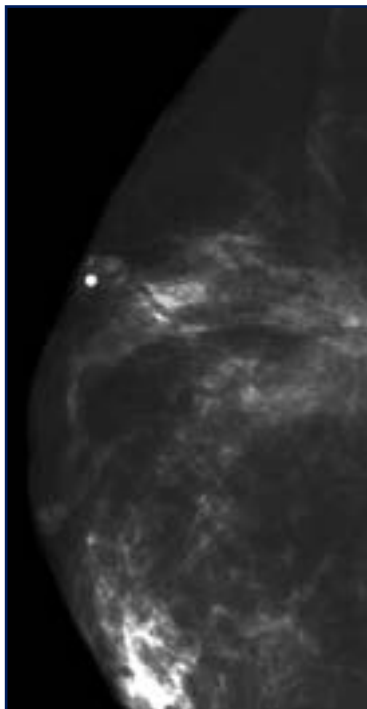


Figure 2: R-CC

### Case 6

A 70 year-old female with a history of right lumpectomy for malignancy followed by radiation therapy. There is post-surgical deformity in the upper aspect of the breast leading to marked displacement of the nipple identified with a nipple marker.