
The Challenges of Administering Oral Contrast During Enterography: Taste and Texture Matter

**Maria Shonyo, President
Vela Technologies, LLC**

Introduction

Enterography exams produce detailed images of the small intestine and structures within the abdomen and pelvis. Enterography is used to identify and locate problems within the bowel such as inflammation, bleeding, obstructions, and Crohn's disease.¹

Enterography may be performed using either magnetic resonance (MR) or computed tomography (CT).

MR enterography (MRE) is a clinically useful technique for the evaluation of small bowel disease, particularly in younger patients with Crohn's disease.² MRE offers the advantages of multiplanar capability, does not require the use of ionizing radiation, and allows evaluation of bowel wall contrast enhancement, wall thickening, and edema.³

CT enterography (CTE) can be beneficial in the acute setting or for patients who cannot tolerate the longer MR exams.⁴ Better anatomical detail may also be achieved with CT due to its greater spatial resolution.⁵

In either imaging modality, evaluation of the small bowel requires distention and delineation of the small bowel loops, which is usually accomplished through oral administration of a liquid contrast agent.

However, many patients find it challenging to ingest large volumes (typically 1 – 1 ½ liters) of a liquid with a taste or texture they find unpleasant. If the patient is unable to consume the required volume of contrast, many consequences that impact workflow, clinical outcomes, and patient satisfaction can occur. There may be associated economic impacts as well.

This paper will discuss these issues and describe how a more appealing contrast agent can help mitigate the pitfalls associated with incomplete drinking protocols.

What happens when a patient is unable to consume all the contrast agent?

- Imaging may be compromised
- Scan may need to be repeated
- Scan may need to be rescheduled
- Nasogastric (NG) tube may need to be inserted

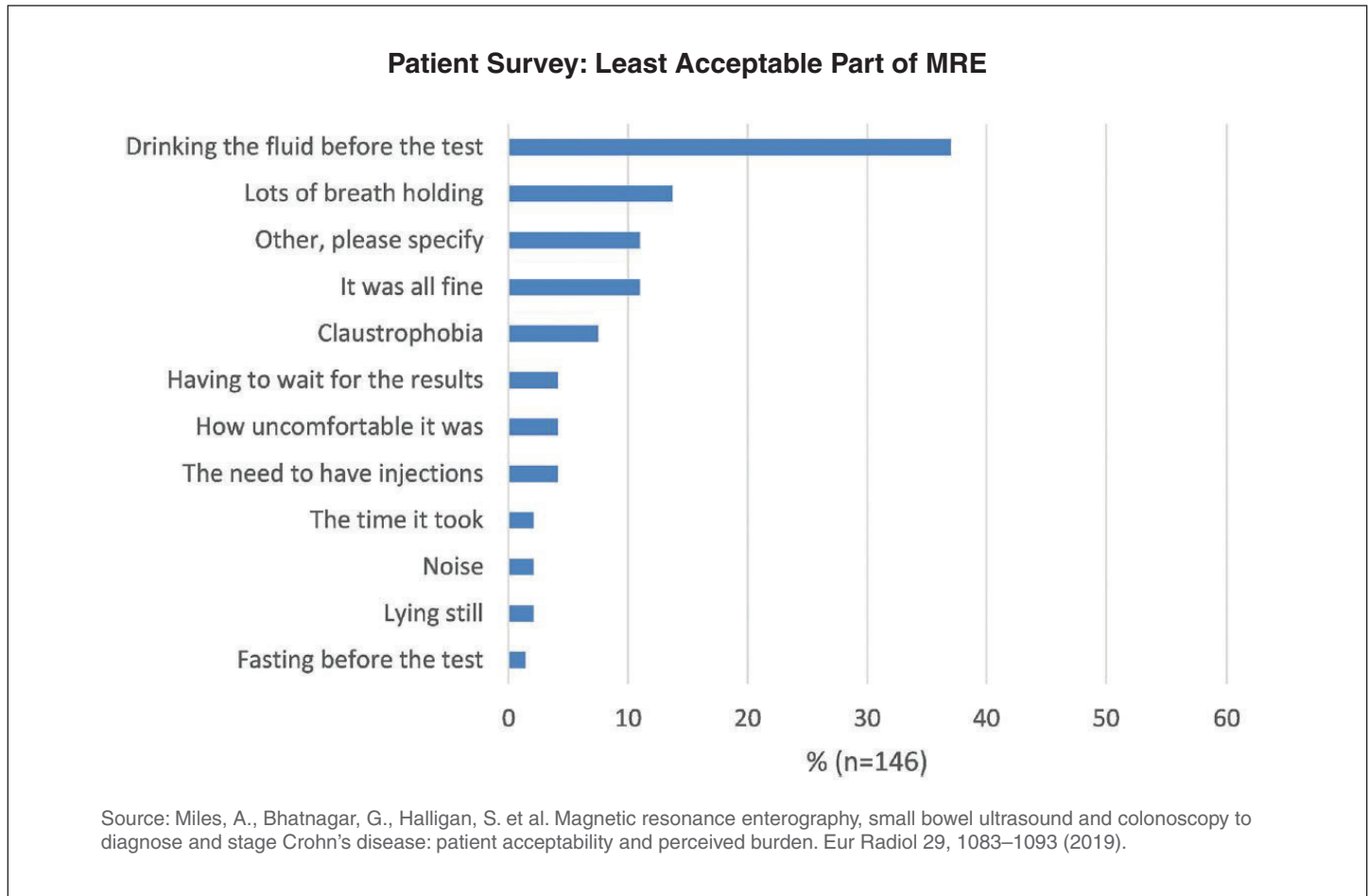
What can I do to improve patients' response to the oral contrast agent?

A blind, random, anonymous survey was completed by MRE and CTE technologists at hospital imaging departments and stand-alone imaging centers across the United States comparing Breeza[®] flavored beverage for neutral abdominal/pelvic imaging (Beekley Medical[®]) to other primary contrast agents.⁶ The results showed patients respond more favorably to Breeza vs other agents, as shown below. Breeza was designed by a radiologist whose patients struggled to complete their drinking protocol due to the taste and texture of other oral contrast agents.

Breeza as Primary Contrast Agent	Other Primary Contrast Agents (including water)
100% of survey respondents said their patients respond "very favorably" or "somewhat favorably" to the taste	79% of survey respondents said their patients respond "very favorably" or "somewhat favorably" to the taste
96% of survey respondents said their patients respond "very favorably" or "somewhat favorably" to the texture	83% of survey respondents said their patients respond "very favorably" or "somewhat favorably" to the texture

Patients Dislike Taste and Texture of Oral Contrast

A study of 146 patients with newly diagnosed or relapsing Crohn's disease showed that 37% said drinking contrast was the least acceptable part of their MRE.⁷



Patients Express Their Dislike:

This patient's experience highlights the difficulty in consuming an unappealing oral contrast agent. Moreover, the utilization of an NG tube can alienate the patient, cause discomfort, and necessitate additional staff.

"I went in for an MRI scan of my small bowel today, and they handed me three big bottles of flavorless barium sulfate [suspension]. I started out okay, but once I had stomached 2/3rds of the bottle, I was gagging constantly and feeling extremely nauseous. I couldn't handle another half a bottle and the rest of the first one, so they couldn't do the scan...I'm really upset and feel like a failure...It's not fair...making us with IBD drink all of that disgusting contrast...I'm just feeling really hopeless and alone...I know the doctor

*said another option would be to get an NG tube and have the barium put in me that way...I feel alone and just feel like a burden for everyone."*⁸

Another patient similarly commented on the challenges of having to consume an unappealing oral contrast agent.

*"It is not uncommon that people have difficulty swallowing the awful contrast fluid...I always have trouble getting it down and keeping it there but at least have had caring and helpful radiology staff."*⁹

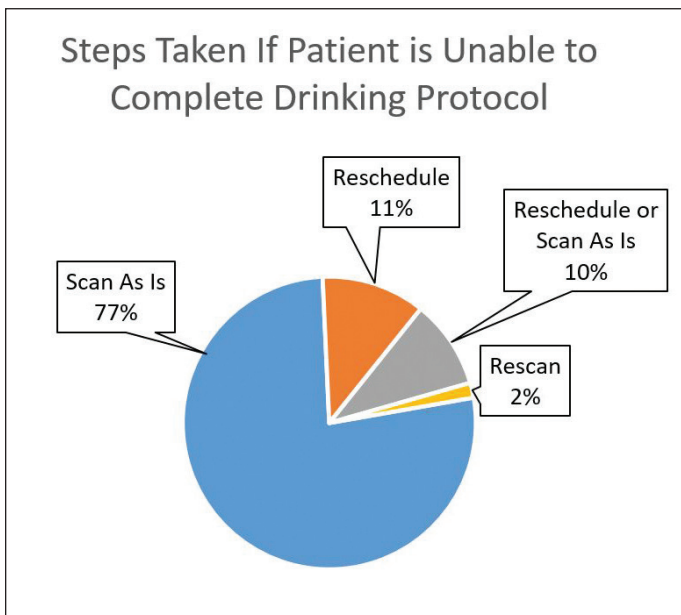
Technologists State Their Challenges:

*"It tastes disgusting and patients rarely can get it all down."*¹⁰

*"[I would like a] better taste to make it easier for our patients."*¹¹

What Happens When Patients Can't Complete the Drinking Protocol?

The results of the survey¹² administered to MRE and CTE technologists showed the vast majority of facilities will scan the patient "as is" even if they have not consumed the full required amount of oral contrast agent. In those situations where the patient is rescheduled, the day's workflow has already been impacted and there is likely a resultant loss in revenue and patient throughput.



Pitfalls of an Incomplete Drinking Protocol

When patients are unable to complete their drinking protocol, one or more of the following pitfalls may occur.

Pitfall #1: Incomplete Luminal Distention

A problem frequently encountered in patients with Crohn's disease undergoing MRE is the inability to drink and retain contrast.¹³ This causes inadequate distention and can falsely cause the appearance of bowel wall thickening and apparent enhancement.¹⁴ Incomplete luminal distention, particularly within the jejunal loops, is a common pitfall encountered during both MRE and CTE.¹⁵ Collapsed bowel may both mimic and hide disease, which may reduce the overall accuracy of the study by leading to false-positive and false-negative assessments, respectively.¹⁶

Pitfall #2: Scan Rescheduled

When an incomplete drinking protocol necessitates rescheduling of the exam, it disrupts the facility's clinical and administrative workflow and can have a negative economic impact. In addition, it is inconvenient for the patient and may cause additional stress and anxiety.

Pitfall #3: Scan Repeated

Similarly, when an incomplete drinking protocol necessitates a rescan, it disrupts the facility's clinical and administrative workflow and can have a negative economic impact. In fact, 70% of survey respondents¹⁷ said their facility is not reimbursed for rescans. Furthermore, not only is it inconvenient for the patient but in the case of CTE, results in additional radiation exposure.

Pitfall #4: NG Tube Insertion: Children are Particularly Challenging

Utilizing an NG tube to administer oral contrast, while an alternative, is not ideal either. Workflow is impacted, additional supplies and staff are required, and it can be unpleasant for the patient. The challenges can be heightened when the patient is a child. Young, unwell children in particular do not like to consume bad-tasting things, especially in the large quantities required for MRE and CTE.¹⁸ Noncompliance in drinking the contrast agent can cause other negative effects during the examination: If the oral contrast agent is objectionable, this can lead to further challenges in cooperation such as holding their breath or an overall inability to be still for the duration of the exam.¹⁹ While an NG tube is an alternative, it is not a desirable situation for patient or parent.²⁰

One CT Supervisor described her experience by saying:

"It was horrible. The children's experience was horrible. The taste and texture of the low-concentration barium suspension was just too much for them - they would vomit and a lot of them would have to have the NG tube placed so we could get it down for them. There was always vomit - didn't matter if there was a NG or not."²¹

What Can Imaging Centers Do to Help Ensure Patients Complete Their Drinking Protocol?

One important step that can be taken to avoid the numerous pitfalls associated with an incomplete drinking protocol is to utilize an oral contrast agent that patients tolerate.

In our survey,²² there was a notable preference for the taste and texture of Breeza® flavored beverage for neutral abdominal/pelvic imaging over other contrast agents, as shown in the figure.

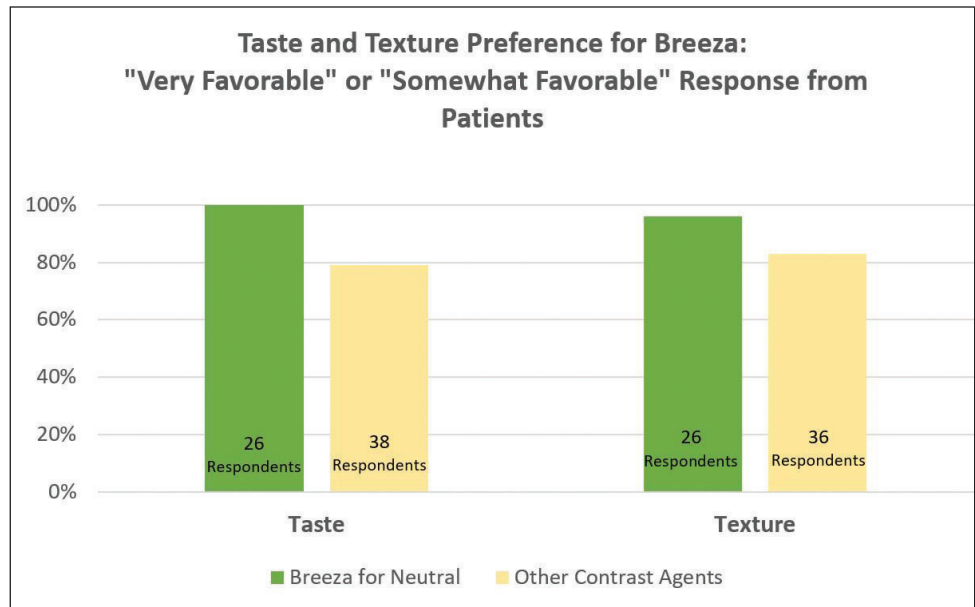
Breeza flavored beverage for neutral abdominal/pelvic imaging has a light, refreshing, lemon-lime flavor to help improve patient satisfaction and encourage patients to consume the full amount. Breeza was designed by a diagnostic radiologist whose patients struggled to complete their drinking protocol due to the taste and texture of other oral contrast agents.

Other Studies Show Similar Preference for Breeza

In one study (Dillman et al), a significantly higher percentage of patients (greater than 30% more) who received Breeza flavored beverage for neutral abdominal/pelvic imaging completed their drinking protocol compared with patients who received a low-Hounsfield barium sulfate suspension.

Specifically, 84.8% of patients completed the prescribed oral preparation when randomized to Breeza, whereas only 51.5% completed the prescribed preparation when randomized to barium sulfate suspension. It was found that on average, a significantly greater volume of Breeza was consumed when compared with the barium sulfate suspension.²³

The study authors suggest that this higher consumption may relate, in part, to significantly higher taste and texture scores for Breeza versus the barium sulfate suspension



(6.1 vs 2.7 for taste and 7.3 vs 3.6 for texture, where 0=very bad taste/texture and 10=very good taste/texture) and may reflect superior patient acceptance and tolerability according to the study authors, who concluded that patients receiving Breeza are more likely to ingest the entire prescribed volume. In particular, the observation that 50% of patients who attempted an oral contrast rescue, i.e., were offered Breeza in an attempt to reach the prescribed volume, could ultimately ingest the total prescribed volume of oral contrast provides additional evidence that Breeza may have better patient acceptance and tolerability than the barium sulfate suspension.²⁴

Another study (Kolbe et al) showed that Breeza® flavored beverage for neutral abdominal/pelvic imaging was strongly preferred over low-Hounsfield-value barium sulfate suspension with respect to taste and scored similar in preference to water. The authors noted that the volume of agent ingested has an effect on preference as well. In their study of adults age 18-60, both the Breeza flavored beverage at the lower volume and water alone scored significantly better with respect to ease of drinking and willingness to repeat the drinking protocol compared with the low-Hounsfield-value barium suspension at either volume.²⁵

Technologists Share the Positive Impact on Their Department After Implementing Breeza Flavored Beverage

While patient acceptance is critical for a successful drinking protocol, a more tolerable oral contrast agent can positively impact workflow and image quality in addition to patient satisfaction.

One department supervisor witnessed how changing to Breeza® impacted her workflow and administration of NG tubes.

“Since implementing Breeza, I don’t need to ‘nag’ pediatric patients to drink, NGs are down, and they’re able to scan patients within the allotted 60-minute time frame. Schedules remain undisrupted and child life services doesn’t need to be involved.”²⁶

This testimony is affirmed by a retrospective study²⁷ of 504 pediatric patients who underwent CTE or MRE which showed a reduction in NG tube (NGT) administration after implementing Breeza as the primary oral contrast agent.

“Since we have integrated the flavored beverage into our practice, requests for NGT administration have been nearly eliminated in children, such that since the conclusion of this study we stopped offering it as a clinical service for enterography. This change has been well received by patients and their families, clinicians, and radiologists and radiology department personnel, while maintaining high quality diagnostic enterography exams in children.”²⁸

Summary and Conclusions

When patients find the oral contrast agent unappealing or unacceptable, they often struggle to complete their drinking protocol, which can result in many negative consequences for the technologist and the facility. Utilizing an oral contrast

agent with a taste and texture that patients prefer is an easy way to minimize these consequences. Breeza flavored beverage for neutral abdominal/pelvic imaging has been shown to have a more favorable response from patients compared to other oral contrast agents.

Breeza® flavored beverage for neutral abdominal/pelvic imaging has a light, refreshing, lemon-lime flavor and appealing bottle to help improve patient satisfaction and encourage patients to consume the full amount.



References:

1. Radiologyinfo.com, retrieved from <https://www.radiologyinfo.org/en/info.cfm?pg=CTenterography>.
2. Damian J. M. Tolan, Rebecca Greenhalgh, Ian A. Zealley, Steve Halligan, Stuart A. Taylor, MR Enterographic Manifestations of Small Bowel Crohn Disease, Radiographics, Vol 30, No 2, March 8, 2020, retrieved from <https://pubs.rsna.org/doi/10.1148/rg.302095028>.
3. Ibid.
4. Rakesh Sinha, Intestinal Imaging: The Last Frontier, J Gastrointestinal Abdominal Radio ISGAR, 2018, retrieved from <https://www.thieme.in/jgar-isgar/jcirpdf/Intestinal-Imaging-The-Last-Frontier.pdf>.
5. Ibid.
6. Blind, random, anonymous survey conducted in April 2020 with MRE and CTE technologists across the U.S.
7. Miles, A., Bhatnagar, G., Halligan, S. et al. Magnetic resonance enterography, small bowel ultrasound and colonoscopy to diagnose and stage Crohn’s disease: patient acceptability and perceived burden. Eur Radiol 29, 1083–1093 (2019). <https://doi.org/10.1007/s00330-018-5661-2>, retrieved from <https://link.springer.com/article/10.1007%2Fs00330-018-5661-2>.
8. Couldn’t drink the contrast, Crohn’s Forum, retrieved from <https://crohnsforum.com/threads/couldnt-drink-the-contrast.52377/>.
9. Ibid.

-
10. Open-ended responses from blind, random, anonymous survey conducted in April 2020 with MRE and CTE technologists across the U.S.
 11. Ibid.
 12. Blind, random, anonymous survey conducted in April 2020 with MRE and CTE technologists across the U.S.
 13. Roopa Ram, David Sarver, Tarun Pandey, Carey L Guidry, and Kedar R Jambhekar, Magnetic resonance enterography: A stepwise interpretation approach and role of imaging in management of adult Crohn's disease, *Indian J Radiol Imaging*. 2016 Apr-Jun; 26(2): 173–184, retrieved from <https://pubmed.ncbi.nlm.nih.gov/27413262/>.
 14. Ibid.
 15. Damian J. M. Tolan, Rebecca Greenhalgh, Ian A. Zealley, Steve Halligan, Stuart A. Taylor, MR Enterographic Manifestations of Small Bowel Crohn Disease, *Radiographics*, Vol 30, No 2, March 8, 2020, retrieved from <https://pubs.rsna.org/doi/10.1148/rg.302095028>.
 16. Ibid.
 17. Blind, random, anonymous survey conducted in April 2020 with MRE and CTE technologists across the U.S.
 18. Donald P. Frush, MD, Oral Contrast Agents for Pediatric CT and MR Enterography: It's a Matter of Good Taste, May 8, 2018, *Radiology*, retrieved from <https://pubs.rsna.org/doi/10.1148/radiol.2018180718>.
 19. Ibid.
 20. Ibid.
 21. Donna Pflug, CT Supervisor, Children's Hospital of Pittsburgh.
 22. Blind, random, anonymous survey conducted in April 2020 with MRE and CTE technologists across the U.S.
 23. Jonathan R. Dillman, Alexander J. Towbin, Rebecca Imbus, Julie Young, Erica Gates, Andrew T. Trout, Comparison of Two Neutral Oral Contrast Agents in Pediatric Patients: A Prospective Randomized Study, *Radiology* Vol. 288, No. 1, May 8, 2018, retrieved from <https://pubs.rsna.org/doi/10.1148/radiol.2018173039>.
 24. Ibid.
 25. Amy B. Kolbe, Joel G. Fletcher, Adam T. Froemming, Shannon P. Sheedy, Chi Wan Koo, Krishna Pundi, David H. Bruining, Jeanne Tung, William S. Harmsen, John M. Barlow, and Jeff L. Fidler, Evaluation of Patient Tolerance and Small-Bowel Distention With a New Small-Bowel Distending Agent for Enterography, *American Journal of Roentgenology*, 2016 206:5, 994-1002, May 2016, retrieved from <https://www.ajronline.org/doi/full/10.2214/AJR.15.15260>.
 26. Donna Pflug, CT Supervisor, Children's Hospital of Pittsburgh.
 27. Kolbe, A.B., Haas, L.A., Bartlett, D.J. et al. Comparison of two small bowel distending agents for enterography in pediatric small bowel imaging. *Abdom Radiol* 44, 3252–3262 (2019). <https://doi.org/10.1007/s00261-019-02102-3>.
 28. Ibid.

