

---

# Dermal or Not? The Surprising Question We Find Ourselves Asking in Digital Breast Tomosynthesis

Erin P. Crane, MD  
Erini Makariou, MD

---

When we first adopted digital breast tomosynthesis (DBT) in 2015, the conventional wisdom in the industry was that anything seen in the first five slices was skin-related and presumably benign and that no additional work-up was necessary.

This perception may have stemmed from the early research and other writings published after DBT gained approval in 2011 which relied heavily on the idea of the scroll bar relaying accurate, readily available, location information on the DBT image slices.

This would make “evaluating masses, calcifications, or other findings related to the skin very straightforward on any routine screening exam, without the necessity for additional views to clarify that a mammographic finding is dermal in origin.”<sup>1</sup>

## False optimism regarding lesion localization

When DBT first came out, people in our industry were very optimistic about increased cancer detection rate, decreased false positives, as well as the added benefit of helping with one of the biggest challenges in mammography - lesion localization.

With the advent of DBT, instead of trying to detect early breast cancers from just two images where all tissue details project on top of one another, potentially obscuring small masses, you could now “slice” through a stack of images of breast tissue in small increments utilizing a scroll bar to localize top and bottom or medial versus lateral.

However, anecdotally, we soon noticed that because of the differences in breast tissue compression on the cranio-caudal view and due to the oblique positioning of the medial lateral view, the scroll bar was not 100% accurate, but was more simply a relative localizer.

## Not a true 3 dimensional reconstruction

This is something that had been noted by others as well. In DIGITAL BREAST TOMOSYNTHESIS (DBT) GUIDANCE, (A supplement to ACR BI-RADS® Mammography 2013), Lee, Destounis, Friedwald, and Newell cautioned that there are several scenarios where lesion location on the scroll bar may appear to contradict true location, as DBT is not a true three-dimensional digital reconstruction:<sup>2</sup>

- Lateral lesions on the CC view will project lower on the scroll bar than on MLO. Medial lesions on CC will project higher than on MLO.
- Superficial lesions tend to roll between projections. Because the breast is repositioned, there can be significant changes in apparent location between views.
- Some manufacturers add 5 extra reconstructed slices on the compression paddle side to eliminate incomplete display of the breast. As a result, lesions will appear to localize closer to the detector side (inferior breast on CC views and lateral breast on MLO views) of the scroll bar in smaller breasts.
- The scroll bar is fixed and represents the thickest part of the breast (usually posterior). Paddle flex may cause the anterior portion of the breast to appear thinner and anterior lesions may localize closer to detector than their true location.

## Intraparenchymal lesions that appeared dermal

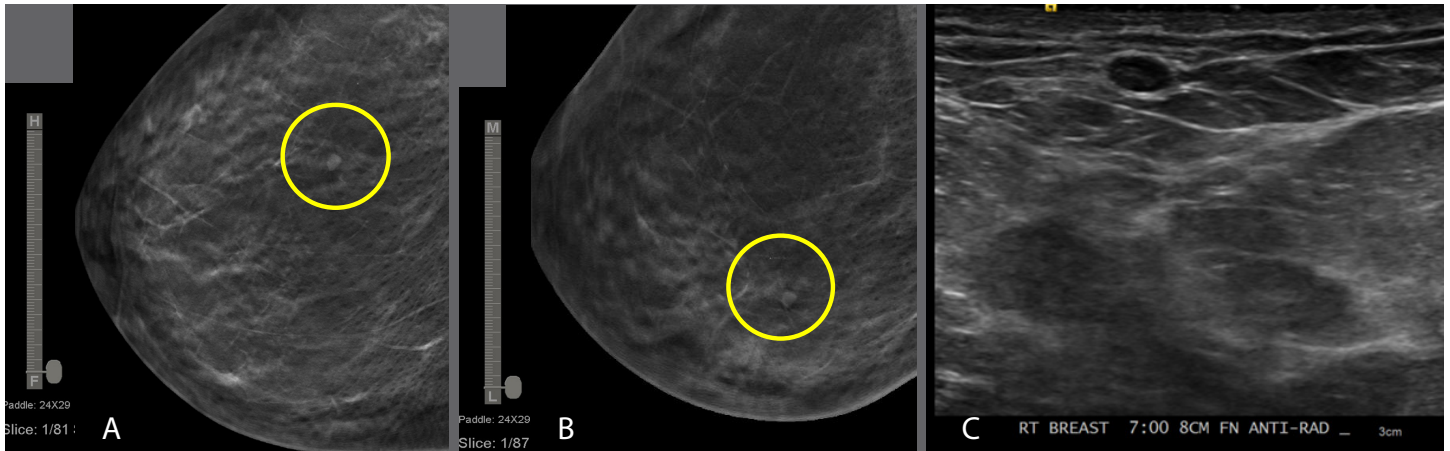
This is what we experienced as well after implementing DBT. We found several instances of lesions that looked like they were within the skin, but in actuality, were not.

We started seeing cases where we were not certain the lesion was within the skin, despite being on the first slice of a DBT stack.

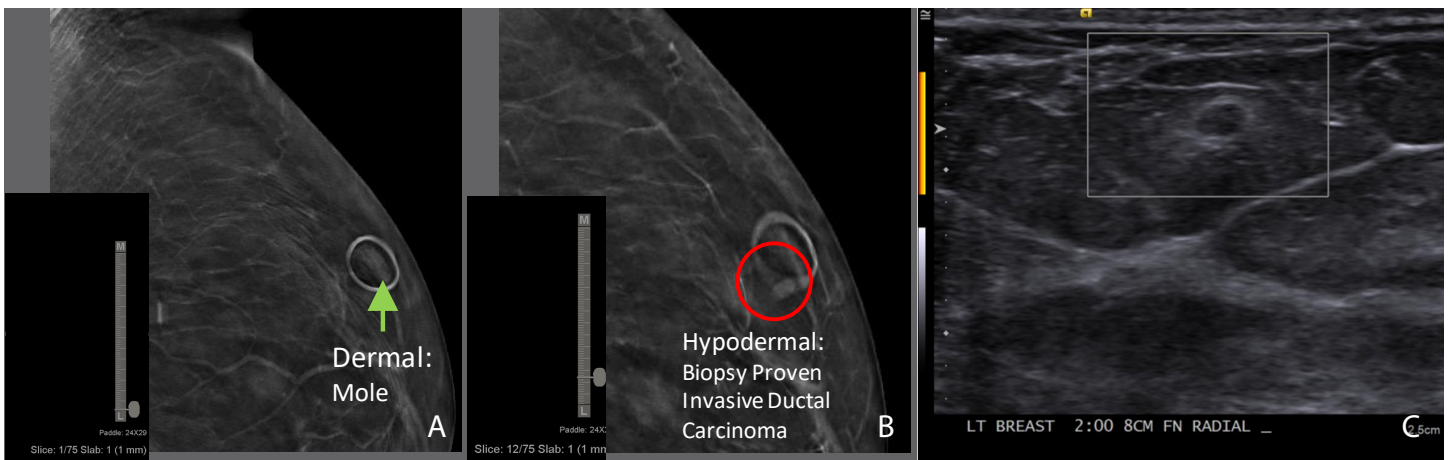
We would perform an ultrasound to further investigate; and found some cases which were not on the skin at all. They were actually within the breast tissue, and some of them were indeed cancers.

Therefore, we learned with these cases that the first 5 slices do not universally indicate that a lesion is benign. Despite advances in technology, localization of masses utilizing DBT is relative and imprecise due to many factors including compression, positioning, breast size and shape, just to name a few variables.

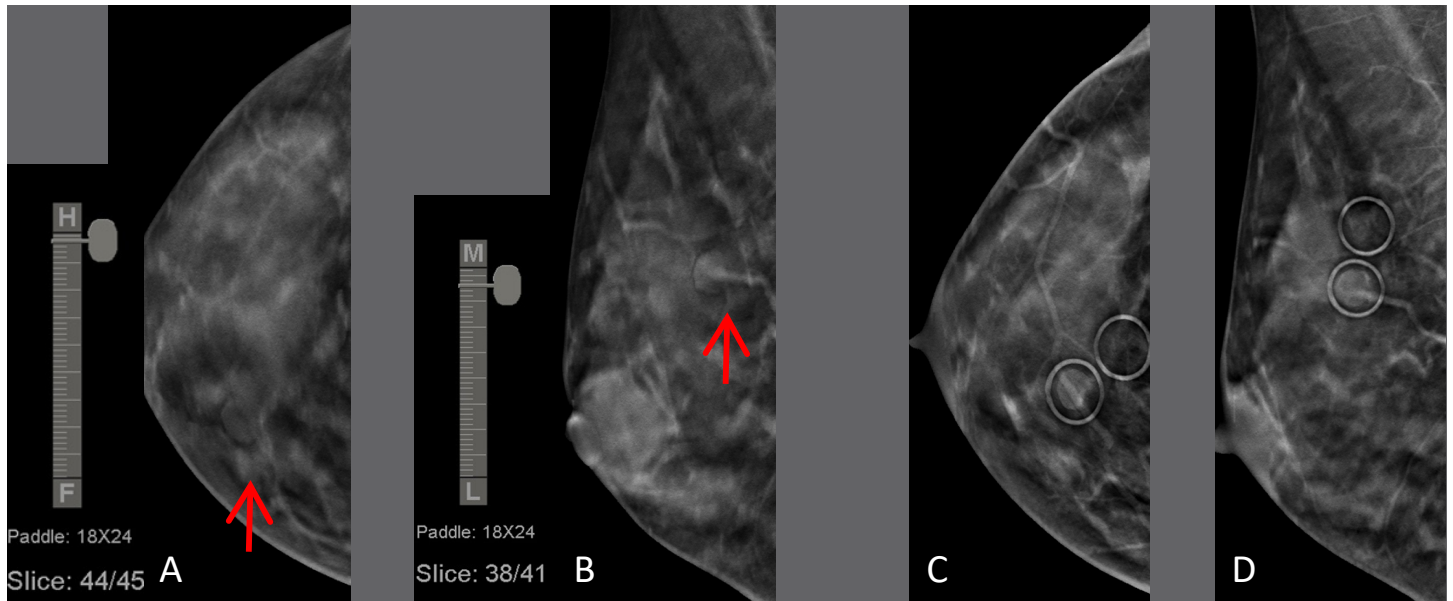
Case #1: 40-year-old asymptomatic female called back from screening mammogram to evaluate a circumscribed, superficial mass localizing to the first image on DBT on both CC and MLO (A, B). Despite localizing to the most superficial DBT slices, targeted ultrasound revealed a benign cyst in the subcutaneous fat (C).



Case #2: Called back from screening mammogram to further evaluate superficial mass just deep to the skin (slice 12, B) in the upper outer left breast, separate from a mole on the skin (slice 1, A). On diagnostic evaluation she had a circumscribed hypoechoic mass with hyperechoic rim, biopsy proven invasive ductal carcinoma (C).



Case 3# 40-year-old female called back from baseline screening mammogram for further evaluation of a superficial mass in the superior/medial right breast (A,B). On diagnostic evaluation, mass corresponds to a clinically evident mole denoted by mole markers (C,D).



The detector plate at the inferior CC view and lateral aspect of the MLO view, is always hard and flat under compression. The paddle (superior on CC and medial on MLO) however, is plastic and has some flexibility.

Therefore, a lesion that is closer to the detector plate can look, under compression, like it is inseparable from, or flush, with the dermis/skin.

The first slice does indeed represent skin, however with increasing compression, a lesion from the subjacent hypodermis or anterior parenchyma could be superimposed on slices 1-5.

### Seeing the value of marking skin lesions in DBT

As we began documenting these cases<sup>3</sup>, we also realized how important it was to mark skin lesions in addition to palpable areas and scars.

Superficial lesions are commonly encountered on mammography. While DBT, in some cases, can clearly define a superficial finding as a benign, dermal entity, there are instances where superficial lesions initially favored to

be dermal are conclusively localized as intraparenchymal during diagnostic evaluation.

As radiologists, we need to guide technologists to clearly indicate moles, skin tags, or sebaceous cysts. There are times you may see them on mammography, but other instances they are not readily visible.

We found it very helpful to ask the technologists to go back and mark any visible moles so that we could be certain whether a finding was indeed dermal.

### Conclusion

DBT is extremely helpful at defining and suggesting findings are superficial benign dermal entities, but it has its limitations.

Air halos, caves of Kopans, and superficial location on the DBT stack lend support to dermal location. However, as we have experienced, caution is indicated. As we have depicted here, and in our experience, cancers can be superficial in location, therefore, we continue to support the continued use of mole markers on DBT.

## About the Authors:



**Erin Patricia Crane, MD,** is a board-certified radiologist and assistant professor of radiology affiliated with MedStar Georgetown University Hospital specializing in women's imaging.



**Erini Makariou, MD,** is a board-certified radiologist and professor of radiology affiliated with MedStar Georgetown University Hospital and MedStar Montgomery Medical Center in Washington, DC, specializing in women's imaging and neuroradiology.

The authors declare no conflict of interest.

---

## References:

1. Jeong Mi Park, MD, "Breast Tomosynthesis: How I Read It," Business Intelligence, November 28, 2011, <https://www.radiologybusiness.com/topics/business-intelligence/breast-tomosynthesis-how-i-read-it>, accessed on March 2, 2020
  2. Carol H. Lee, MD, et al, "DIGITAL BREAST TOMOSYNTHESIS (DBT) GUIDANCE (A supplement to ACR BI-RADS® Mammography 2013)," American College of Radiology, 2013, <https://www.acr.org/-/media/ACR/Files/RADS/BI-RADS/BI-RADS-Digital-Breast-Tomosynthesis-Supplement.pdf>, accessed on March 2, 2020
  3. Erin Crane, et al., "On the Edge: Pictorial Review and Imaging Assessment of Superficial Abnormalities on Digital Breast Tomosynthesis (DBT)," Poster Session, ARRS Annual Meeting, Washington, D.C., April 22-27, 2018
-