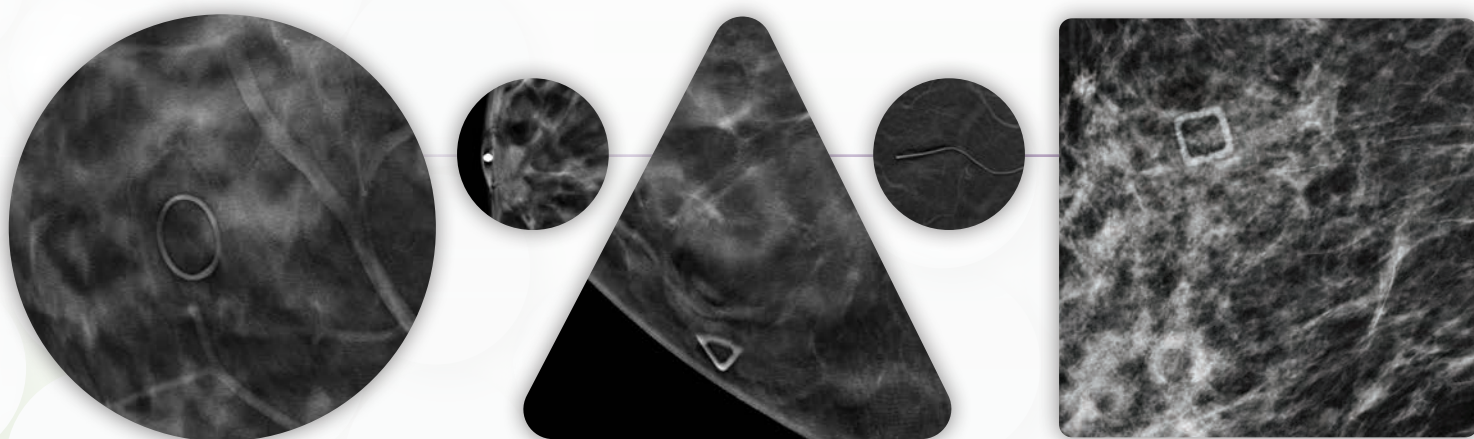


The Beekley Skin Marking System® for Mammography



Clear communication
for precise interpretation.

The Beekley Skin Marking System® - Table of Contents



Benefits of Skin Marking 2

Nipple Markers 3

Used as a reference to identify nipple location



Mole Markers 5

Indicates if raised moles or nevi are present



Scar Markers 7

Clearly defines a scar from a previous surgery



Palpable Mass Markers 9

Identifies the location of a palpable abnormality



Non-Palpable Area of Concern or Pain Markers 11

Communicates a non-palpable area of concern or focal pain

ACR Recommendations on Skin Marking 13

The Beekley Medical® Difference 14

Benefits of Skin Marking

The Beekley Skin Marking System® for Mammography provides clear communication for radiologists with an effective way to identify nipples, raised moles, surgical scars, palpable masses, and non-palpable areas of concern or pain for precise interpretation. As a result, mammograms can be more accurate, and callbacks can be reduced.

The system consists of five different and distinctive shapes. A circle appearing on the image indicates a raised mole. A line visibly shows the location, shape, and length of a previous surgery, a triangle symbolizes a palpable mass, a pellet is used to mark a nipple, and a square identifies non-palpable areas of concern or pain.

Breast imaging centers using the Beekley Skin Marking System for either 2D full field digital mammography (FFDM) or digital breast tomosynthesis (DBT) report better communication, fewer questions, reduced need for additional views, better interpretation when comparing to priors, and improved permanent documentation for future interpretation.

- Nipple markers improve accuracy and can be used on every patient to differentiate a retroareolar finding from the nipple
- Mole markers can eliminate questions and help reduce avoidable callbacks
- Scar markers act as a reference point and eliminate confusion by identifying the location of a biopsy or previous surgery
- Palpable mass markers readily identify the symptomatic area
- Non-palpable areas of concern or focal pain markers indicate the precise location of an area in question

Improving standardization can lead to fewer misinterpretations, lessen the chance of resultant lawsuits, and reduce confusion when a patient has imaging exams performed at different facilities.¹

Radiologists who use the Beekley Skin Marking System comment on the benefits:

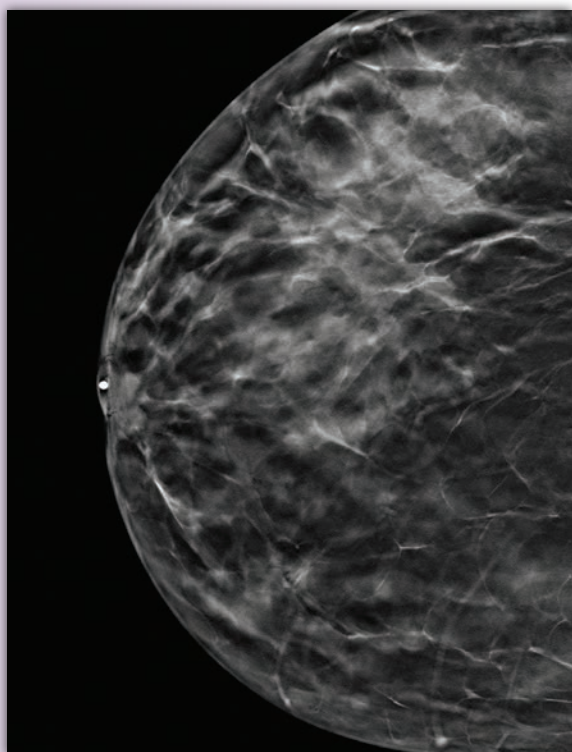
"Radiologists like myself, who read at multiple sites, additionally benefit from consistent use of a skin marker shape system. It provides standardization and an easier way to identify specific areas of concern."

~ Terri-Ann Gizienski, MD, Director Breast Imaging, Pittsburgh, PA

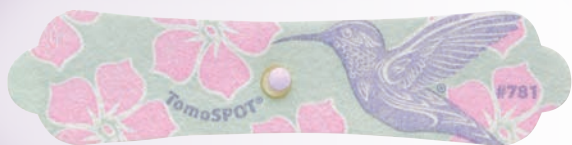"Skin markers save the patient extra tests and may help reduce anxiousness. I think they appreciate that we're noticing the details and taking the extra time to go through their history."

~ Joseph Benjamin, MD, Lead Interpreting Physician, Cincinnati, OH

Beekley Medical® Nipple Markers



Pellet = Nipple



TomoSPOT® REF 781

Beekley Medical nipple markers are available in many styles, adhere securely to the breast, and image brightly with minimal-to-no “slinky” artifact.

Nipple markers improve accuracy and can be used on every patient to differentiate a retroareolar finding from the nipple

- Avoids potential confusion that may cause a patient to return unnecessarily for additional imaging if the nipple rolls back or under which can present as a breast nodule.
- Helps localize the nipple in both FFDM and DBT imaging when the nipple is not prominent.
- Helps the radiologist determine if there is an inverted nipple which could be mistaken for a retroareolar mass.

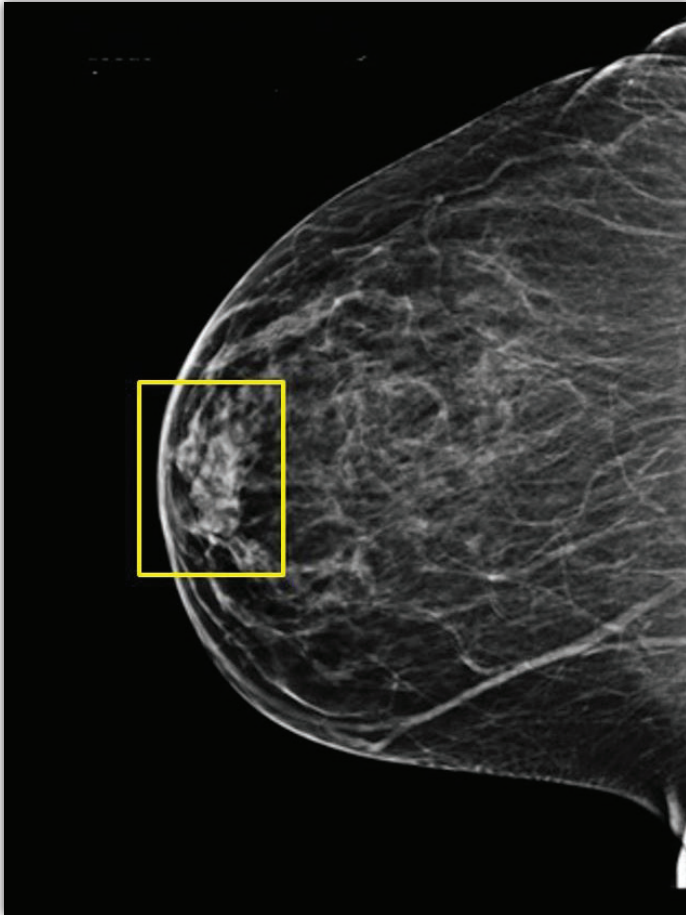
Measuring back to an area of concern

- Highlights the precise location of the suspected lesion for diagnostic imaging, stereotactic biopsies, or ultrasound.
- Acts as a reliable landmark that can be used as a precise measuring tool for nipple-to-lesion measurements.
- Helps to locate the nipple on patients with architectural distortion due to prior surgery.

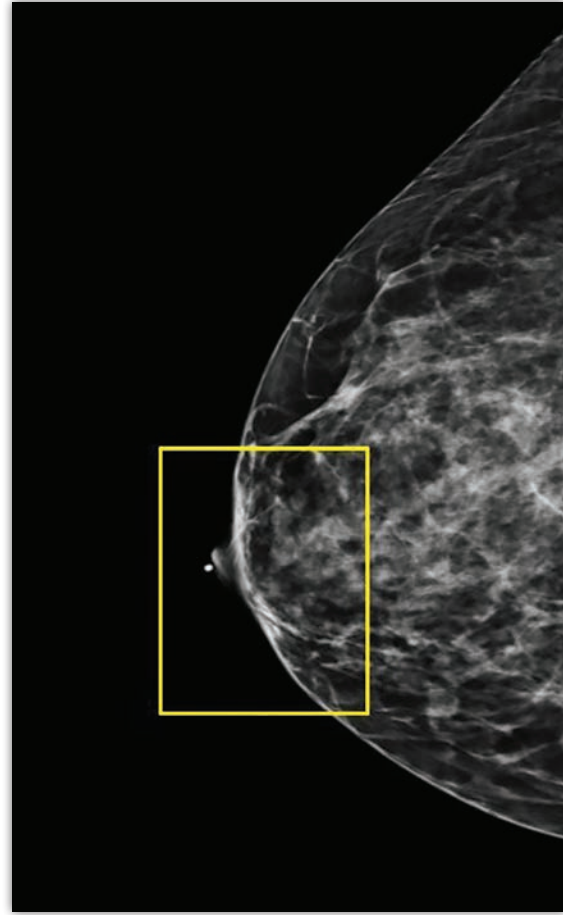
Positioning benefits

- Assists in identifying medial or lateral deviation which can lead to missing tissue – “the nipple points towards the missing tissue.”
- Helps to ensure breast is completely lateral on true lateral views.
- Promotes good positioning and verifies nipple is in profile.
- Records and simplifies year-to-year comparisons to help confirm patient positioning.

The DBT images below illustrate an example of how a nipple marker was successfully used. 93% of facilities reported using a pellet for a nipple marker.²



This 42-year-old female patient presented for her yearly routine screening mammogram utilizing DBT. This right CC view shows an opacity in the anterior aspect of the breast in the retroareolar area. A significant number of cancers occur in this area, so it is important to determine if it is a mass. Unfortunately, the patient had already gone home.

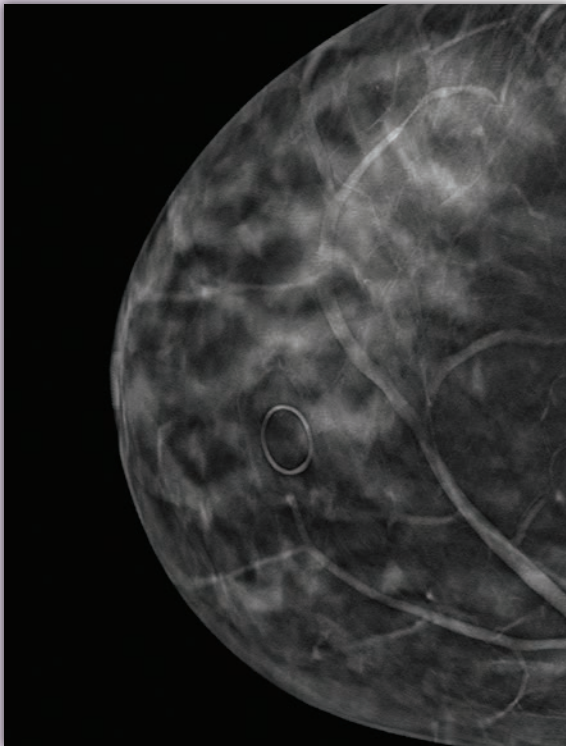


The patient was called back and a marker was placed on the nipple. An additional "nipple in profile" view was taken. The opacity was no longer visualized. It was confirmed that the opacity seen on the prior DBT image was the nipple superimposed over the anterior aspect of the breast. If nipple markers were used consistently, this callback could have been prevented and the associated patient anxiousness and additional radiation exposure could have been eliminated.

"As radiologists, we want to minimize the need to call patients back unnecessarily while ensuring a new cancer is not overlooked. Consistent use of skin markers is instrumental in achieving this objective. I am committed to doing anything I can to minimize patient anxiety, inconvenience, and radiation exposure."

~ Terri-Ann Gizienski, MD, Director Breast Imaging, Pittsburgh, PA

Beekley Medical® Mole Markers



Circle = Mole



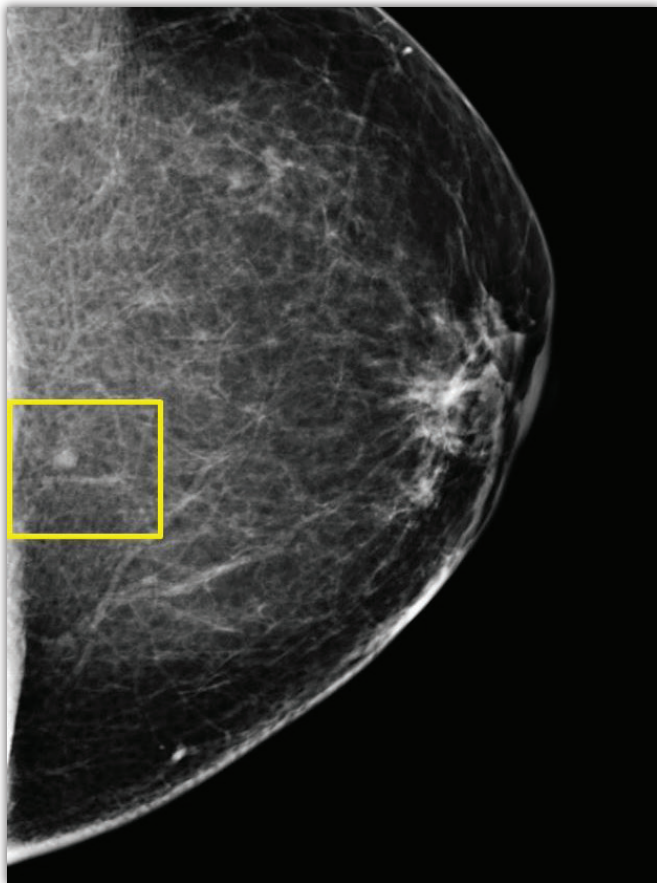
TomoSPOT® REF 782

Mole markers can eliminate questions and help reduce avoidable callbacks

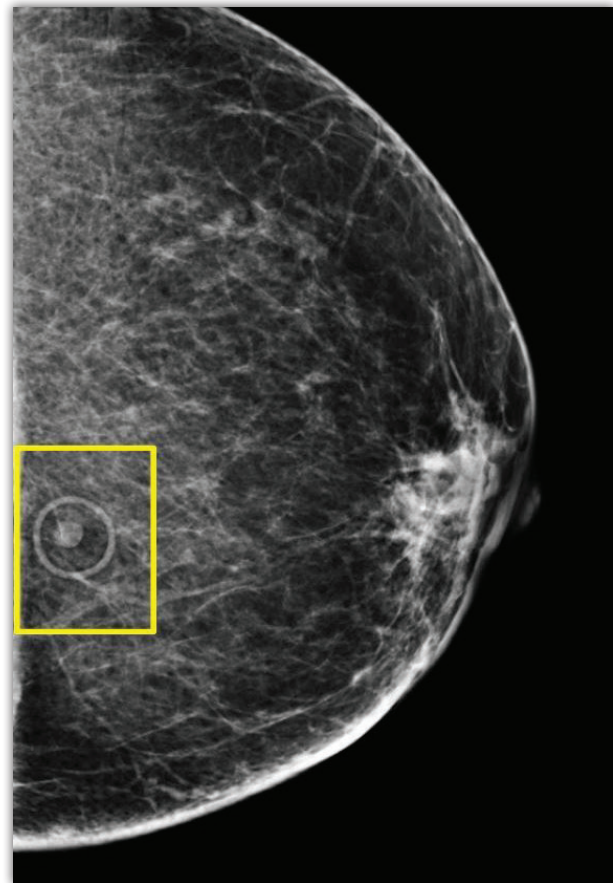
- Detects a mole as not an area of concern since moles can localize to deeper slices and result in a recall.
- Helps differentiate moles from superficial cancers.
- Identifies the accurate position of anterior moles on a large breast which can vary greatly from year to year due to positioning.
- Reduces interpretation time and helps eliminate the need for additional imaging.
- Lessens potential callbacks thus helping to eliminate unnecessary patient anxiousness.
- Provides clear and permanent documentation on patient's images if patient transfers to another location or breast center.

Beekley Medical circular mole markers are offered in ultra-sheer and low-density variants, allowing all tissue detail and calcifications to image within the shadow of the marker.

The DBT images below illustrate an example of how a mole marker was successfully used. 93% of facilities reported using a circle-shape skin marker to mark moles.³



This 62-year-old female patient presented for a screening DBT mammogram. The radiologist described an indeterminate low-density circumscribed mass as seen in the yellow box, which is very posterior on this left CC view. Reading through the DBT slices, it was unclear if the mass was at the skin line or just under the surface.



The patient was called back and circular mole markers were used to mark all moles on the breast, resulting in this mass being immediately identified as a skin mole. If the marker had been used on the initial screening exam – the recall, the associated anxiety, cost, and extra dose of radiation could have been avoided.

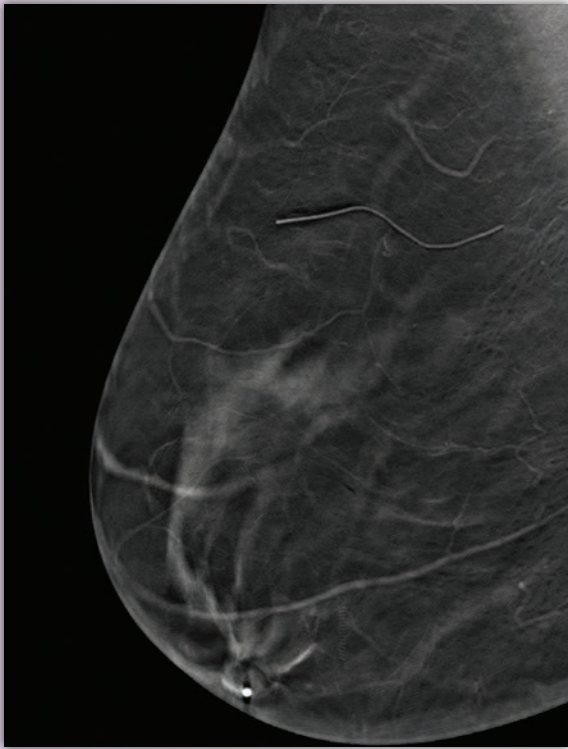
"Using the circular mole marker to confirm the mole is in the dermal layer means I know I'm done and can move on."

~ Joseph Benjamin, MD, Lead Interpreting Physician, Cincinnati, OH

"Superficial lesions are commonly encountered on mammography. While DBT, in some cases, can clearly define a superficial finding as a benign, dermal entity, there are instances where superficial lesions initially favored to be dermal are conclusively localized as intraparenchymal during diagnostic evaluation. As radiologists, we need to guide technologists to clearly indicate moles, skin tags, or sebaceous cysts. There are times you may see them on mammography, but other instances they are not readily visible."

~ Erin Crane, MD and Erini Makariou, MD, Washington, DC

Beekley Medical® Scar Markers



Line = Surgical Scar



TomoSPOT® REF 783

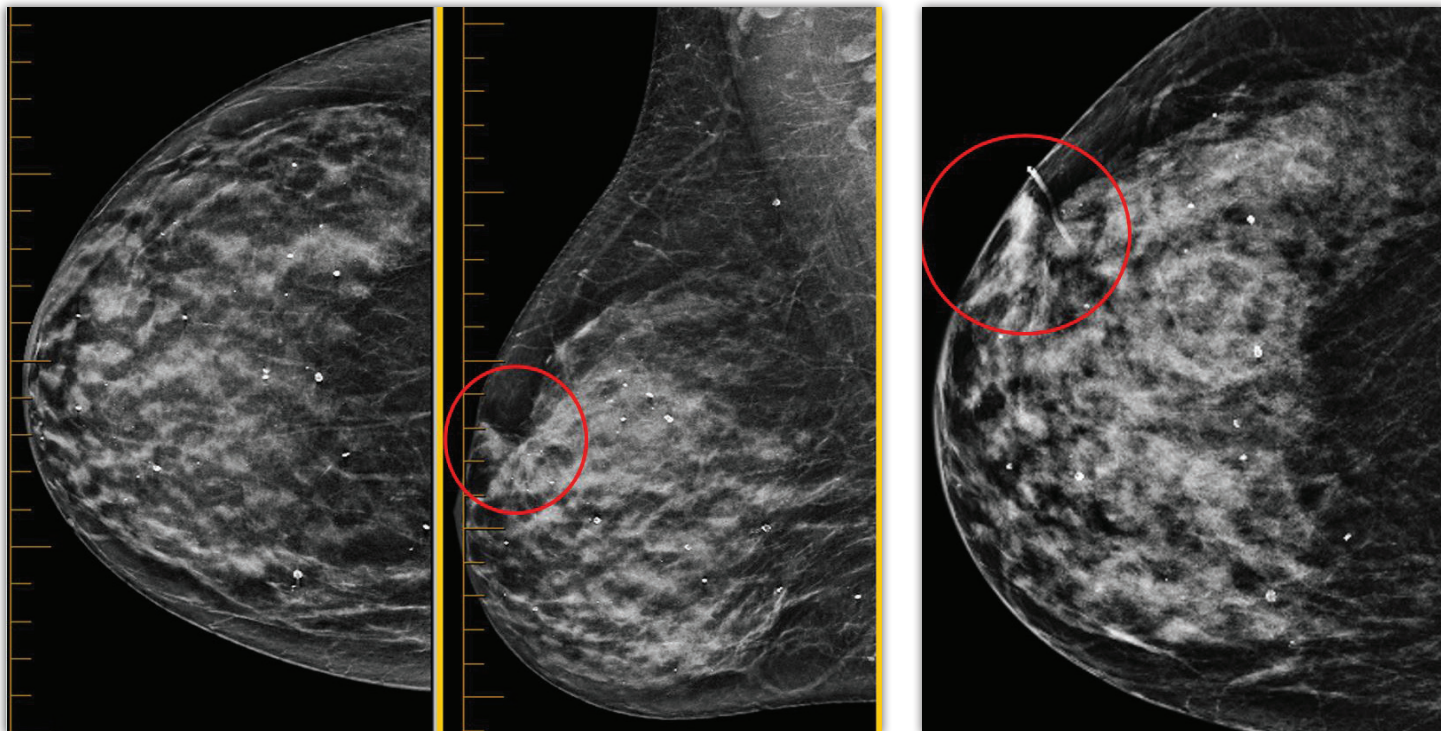
Scar markers act as a reference point and help eliminate confusion by identifying the location of a biopsy or previous surgery

- Differentiates suspicious lesions from benign architectural distortion as a result of surgery. DBT often reveals architectural distortion, especially from benign surgeries, that were not evident in FFDM. Scars that are not marked can result in unnecessary callbacks.
- Distinguishes between a new or recurring cancer and normal post-surgical changes which have many characteristics that are consistent with an evolving cancer including calcifications, skin thickening, architectural distortion, puckering or retracted skin, and a spiculated mass.
- Clarifies distortion or asymmetry of the local breast architecture.
- Identifies prior biopsy site. Calcifications found in the area marked with a scar marker can be examined relative to their location.
- Maintains a reference point to the original surgery from year to year for easy correlation of the surgical history and mammographic findings.

Linear scar markers clearly communicate the location, length and shape of a post-surgical scar without obscuring underlying tissue detail.

Scar markers can be used on excisional biopsy scars, keloid scars, reduction mammoplasty, mastopexy, augmentation, explantation, scars from thoracic surgery, chest tube, or prior port placement.

The DBT images below illustrate an example of how a scar marker was successfully used. 97% of facilities reported using a line-shape skin marker to mark scars.⁴



These images are from a 65-year-old female patient who presented for a DBT screening mammography. There is some new architectural distortion in the superior right breast, as seen here in the red circle on the MLO view. The patient was recalled, and the architectural distortion persisted during the DBT spot compression view. When meeting with the patient for a more detailed history, she remembered an excisional biopsy years earlier and the scar is noted in the lateral right breast.

The CC view is repeated with a linear scar marker in place, confirming the architectural distortion is related to the previous surgery. This case demonstrates the need for a good medical history as well as thorough visual checks by the mammographer and the use of the appropriate skin markers.

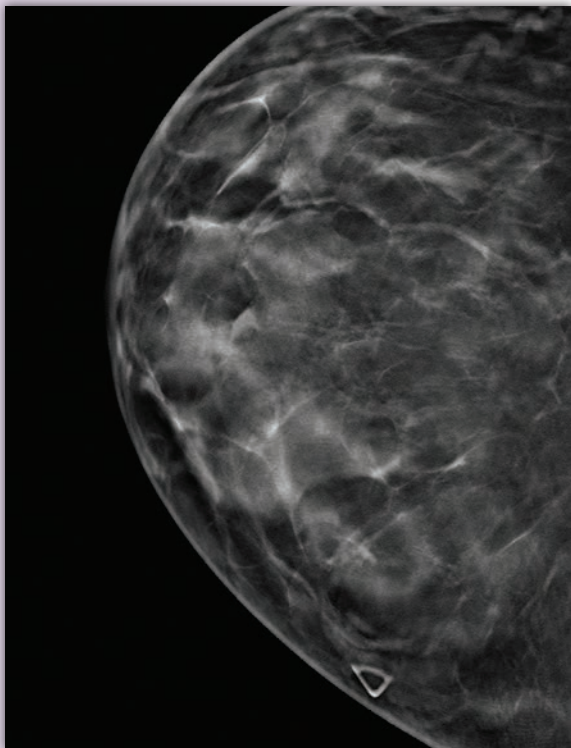
"Consistently marking with this visual communication system aids patients by reducing call backs and potentially saving them from additional views and added radiation, all of which contribute to reducing the patient's anxiousness and enhancing the overall experience."

~ Michael Linver, MD, FACR, FSBI, Albuquerque, NM

"Using skin markers lets you correlate with 100% certainty that it is the same finding on the two views."

~ Christina V. Jacobs, MD, Director of Breast Imaging, Kalamazoo, MI

Beekley Medical® Palpable Mass Markers



Triangle = Palpable Mass



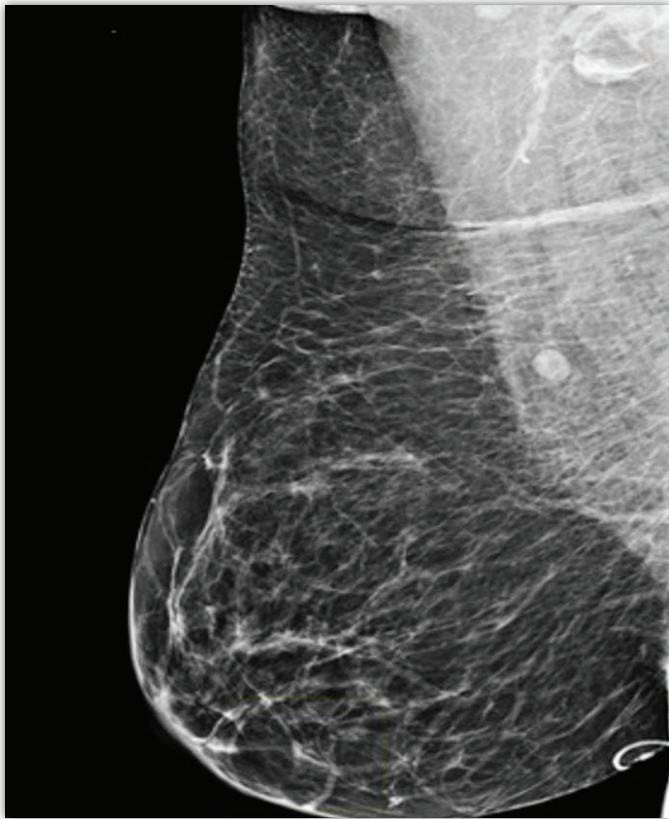
TomoSPOT® REF 784

Palpable mass markers readily identify symptomatic areas

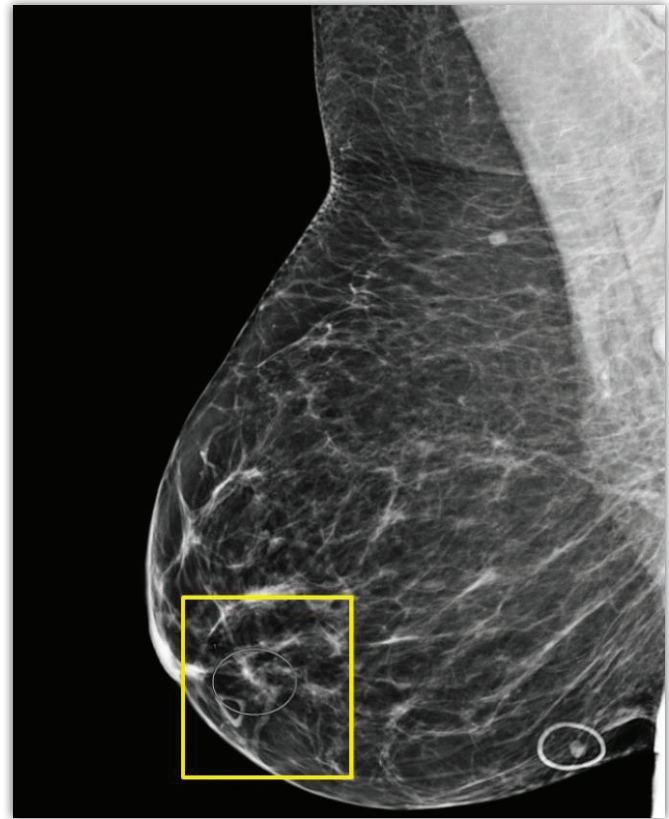- Directs attention to the palpable mass on the image without obscuring calcifications or other findings.
- Serves as a visual cue for the technologist who can then ensure the marker (and the mass) are within the field light and included on the image. This is especially important if the mass is mammographically occult.
- Helps establish a correlation between the physical findings of what is palpated with what is seen on the image.
- Instills confidence that the palpable abnormality is included on image.
- Documents mass or abnormality on patient's image permanently.
- Reassures patient when told a specific marker is being used to direct the radiologist to the area in question.

A palpable mass marker is the best way to correlate the clinical finding of a palpable mass with the imaging findings.

The DBT images below illustrate an example of how a palpable mass marker was successfully used. 67% of facilities reported using a triangle-shape skin marker to mark palpable masses.⁵



This 68-year-old female patient presented for a screening mammogram utilizing DBT. The patient informed the technologist of a small lump in the right breast, which the technologist did not mark. The technologist also coded the patient as a screening mammogram and did not present the patient to the radiologist for a diagnostic workup of the lump. The exam was read as negative.

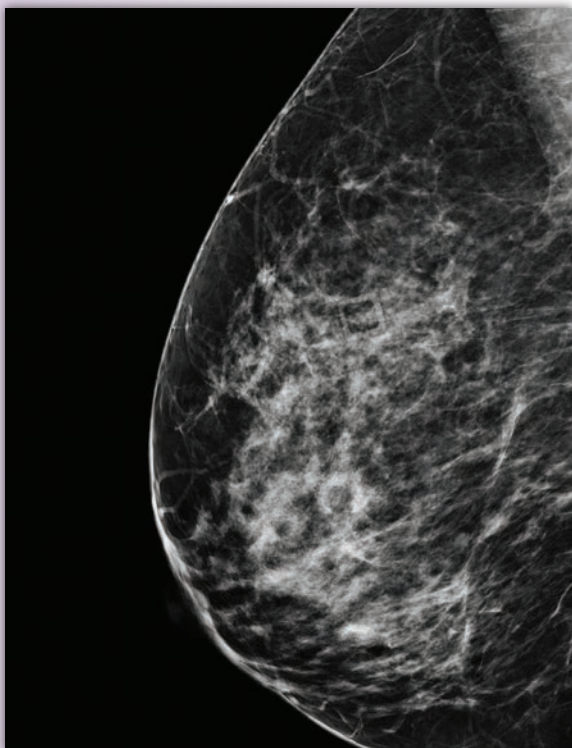


The patient returned six months later, and again complained of a palpable mass in the right breast, which was now marked by the technologist using a triangular palpable mass skin marker as seen in the yellow box. The area correlated with a very small focal asymmetry, which was not a clear mass with DBT and therefore it was not seen in the exam six months earlier. The radiologist ordered an ultrasound. The ultrasonographer used the mass marker as a starting point and quickly located a suspicious sub-centimeter mass which was biopsied and confirmed to be invasive ductal carcinoma.

"We want to minimize the need to call patients back unnecessarily while ensuring a new cancer is not overlooked. Consistent use of skin markers is instrumental in achieving this objective. It is also much more challenging and time consuming without a marker."

~ Terri-Ann Gizienski, MD, Director Breast Imaging, Pittsburgh, PA

Beekley Medical® Non-Palpable Area of Concern or Pain Markers



Square = Area of Concern or Pain

Non-palpable areas of concern or focal pain markers provide a precise location of the area in question

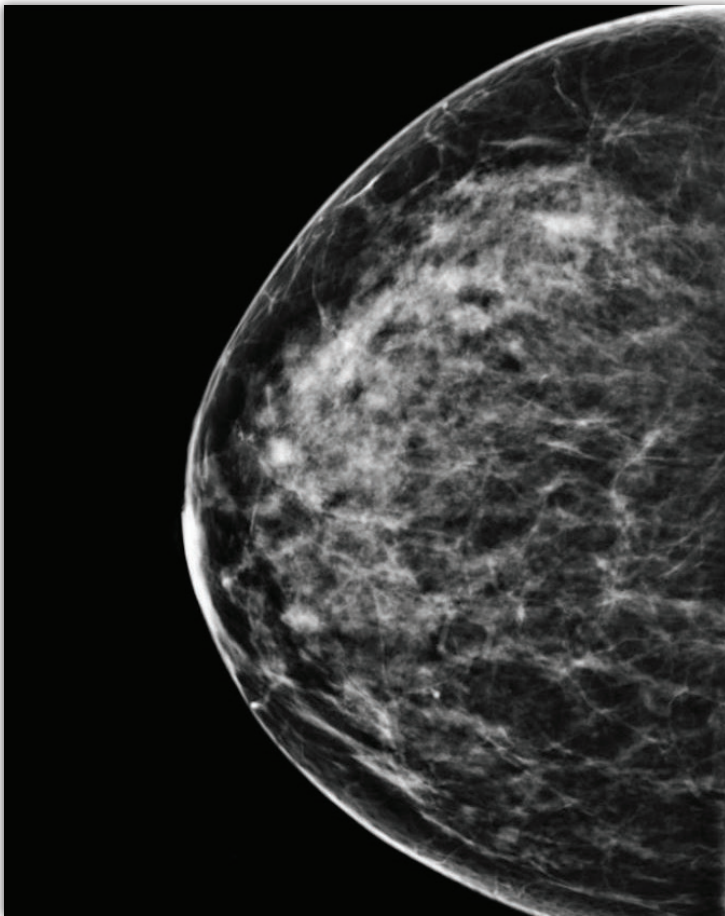
- Localizes an area the patient identifies as painful for the radiologist, and ultrasonographer if an ultrasound is subsequently ordered.
- Gives radiologist confidence that area of focal pain was included on image - especially if there is nothing mammographically evident.
- Facilitates faster read time with immediate identification of the area in question.
- Provides permanent documentation as history charts can sometimes get lost.



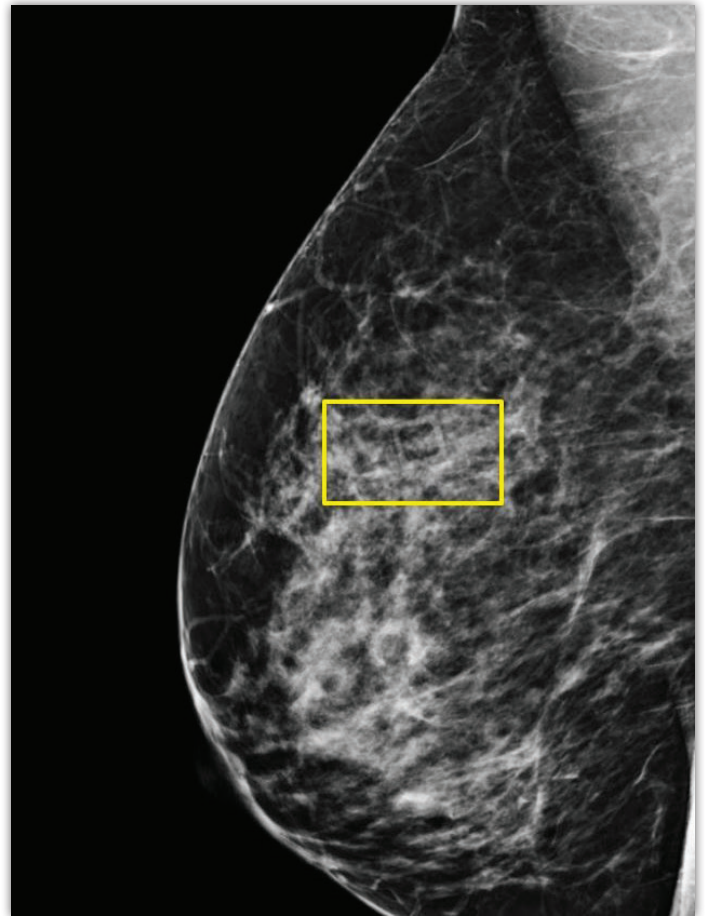
TomoSPOT® **REF** 785

Low density lucent square for communicating an area of focal pain. Also identifies non-topographic areas of concern such as a cyst, bug bite, rash, bruise, or ecchymosis.

The DBT images below illustrate an example of how an area of pain marker was successfully used. 37% of facilities reported using a square-shape skin marker to mark non-palpable areas of concern or pain.⁶



This 42-year-old female patient presented for a diagnostic DBT exam. The patient had focal pain in the upper medial right breast. There was no abnormality present on the CC view of the DBT mammogram in the image seen above. The description of the location of the pain (“upper medial right breast”) was not very specific.



For the MLO view, the square focal pain marker was placed at the site the patient indicated, as seen in the yellow box. As no abnormality was noted to correlate with the skin marker on the DBT images, an ultrasound was ordered. The ultrasonographer targeted the area of non-palpable pain identified by the skin marker. The painful abnormality corresponded with a 1.2 centimeter mass on ultrasound. An ultrasound-guided biopsy was ordered which confirmed an invasive cancer.

“Skin markers save the radiologist time, decrease avoidable callbacks, and improve patient safety”

~ Christina V. Jacobs, MD, Director of Breast Imaging, Kalamazoo, MI

“The square marker catches your eye and forces you to look closer in that area.”

~ Joseph Benjamin, MD, Lead Interpreting Physician, Cincinnati, OH

ACR Amends Skin Marking Protocol for Screening and Diagnostic Mammography

In 2018 the American College of Radiology (ACR) amended their Practice Parameters for the Performance of Screening and Diagnostic Mammography⁷ to include the paragraph below regarding skin markers.

Of note is the term “radiographically distinct” indicating that the area of concern being communicated should be immediately evident by the shape.

The ACR’s recommendation includes using a different marker for moles, palpable masses, and surgical scars.

ACR Recommendations

“Facilities should require consistent use of radiographically distinct markers to indicate palpable areas of concern, skin lesions, and surgical scars. In addition, there should be an indication of the type of underlying lesion denoted by each marker, either as a permanent annotation on the appropriate mammographic image(s) or as a description in the mammography report. It may also be helpful to record such findings on the patient’s intake sheet and/or technologist worksheet.”⁸

The ACR is a trusted source of guidance for radiologists:

“The ACR has always been the voice of the radiologists in this country and has been active in helping radiologists meet the highest possible medical standards.”

~ Michael Linver, MD, FACR, FSBI, Albuquerque, NM

Radiologists comment on the advantages of a standard skin marking protocol:

“In a health system such as ours that has multiple facilities, having a standard protocol for the use of skin markers decreases the chance of misinterpretation and improves communication between the technical staff and the radiologists.”

~ Christina V. Jacobs, MD, Director of Breast Imaging, Kalamazoo, MI

“Uncertainty in regards to imaging findings still occurs on tomosynthesis, which typically increases interpretation time and may lead to unnecessary diagnostic workups for patients. Skin markers continue to add value to interpreting physicians by providing instant visual cues that can help reduce uncertainty and, most importantly, digitally document physical exam findings on mammography.”

~ Alex Merkulov, MD, Associate Professor of Radiology Section Head of Women’s Imaging, Farmington, CT

The Beekley Medical® Difference

A focus on making the lives of everyone we touch a little better

At Beekley Medical, our goal is to help positively impact patients' lives and improve clinical outcomes.

To accomplish this goal, we have a high commitment to investing in the research and development of simple, low cost, disposable products that help medical imaging, surgical, and radiation oncology professionals improve communication, productivity, and patient care.

We partner with our customers, clinicians, and inventors to produce professional products that replace makeshift products or improve upon current methods. We closely monitor our industries to ensure our products meet tomorrow's needs today.

A commitment to quality

Working as a team, Beekley Medical Associates are empowered and committed to meeting and exceeding their internal and external customers' expectations while complying with all Quality Management System processes which assure we meet the requirements of ISO 13485, FDA Quality System Regulations, and all other applicable regulations.

A partner to our communities

Even small companies can make a big difference in the world around them.

Beekley Medical believes firmly in giving back to our communities. A portion of the proceeds from the sales of our Mammography SPOT® skin markers is donated to local and national organizations that fund research, awareness, and early detection programs in the fight against breast cancer.

In addition, Beekley Medical is a proud supporter and sponsor of several educational programs, conferences, professional organizations, and advocacy groups for our imaging community.


Our products are backed by a 100% satisfaction guarantee.
Returns and exchanges are accepted at any time without penalty or restocking fees.

Call 1.800.233.5539 • Fax 1.800.735.1234
Visit beekley.com • Email info@beekley.com

Customers outside the U.S. – Contact your local distributor for pricing and product availability.
To locate a distributor call +1.860.583.4700 or email international@beekley.com

References




1. Importance of Visual Checks Before Mammograms, Olive Peart, Imaging Technology News (ITN), May 31, 2019, retrieved from <https://www.itnonline.com/article/importance-visual-checks-mammograms>.
2. Beekley Medical Skin Marking Survey, November 2017.
3. Ibid.
4. Ibid.
5. Ibid.
6. Ibid.
7. ACR PRACTICE PARAMETER FOR THE PERFORMANCE OF SCREENING AND DIAGNOSTIC MAMMOGRAPHY, Revised 2018 (Resolution 35), Section E, Markers, Part 2 (Page 5), retrieved from <https://www.acr.org/-/media/ACR/Files/Practice-Parameters/screen-diag-mammo.pdf>.
8. Ibid.

 Manufactured by Beekley Corporation
One Prestige Lane, Bristol, CT 06010-7454 USA
Tel: 1.800.233.5539 or +1.860.583.4700
Fax: 1.800.735.1234 beekley.com

BEEKLEY, BEEKLEY MEDICAL, BEEKLEY SKIN MARKING SYSTEM, SPOT, TOMOSPOT, WHEN YOUR DIAGNOSIS MUST BE RIGHT, the Raised Circle, the Raised Triangle, the Raised Square, and the Hummingbird design are Reg. U.S. Pat. & Tm. Off. BEEKLEY, SPOT, and TOMOSPOT are Registered Community Trademarks. BEEKLEY is a registered trademark in Canada.

© 2023 Beekley Corporation. All rights reserved.

WARNINGS & PRECAUTIONS:

- Single Patient Use Only; Do Not Reuse 
- External Use Only; Do Not Ingest or Swallow
- Do Not Place on Compromised Skin
- Remove After Use
- Not Made with Natural Rubber Latex
- Lead-Free 
- Non-Sterile 

If any serious incident occurs in relation to this device, report it to Beekley Medical and to the competent authority of the Member State in which the user and/or patient is established.



EC REP
EMERGO EUROPE
Westervoortsedijk 60
6827 AT Arnhem
The Netherlands

REV: BSMS_BK_0623